



Diagnostic Exercise

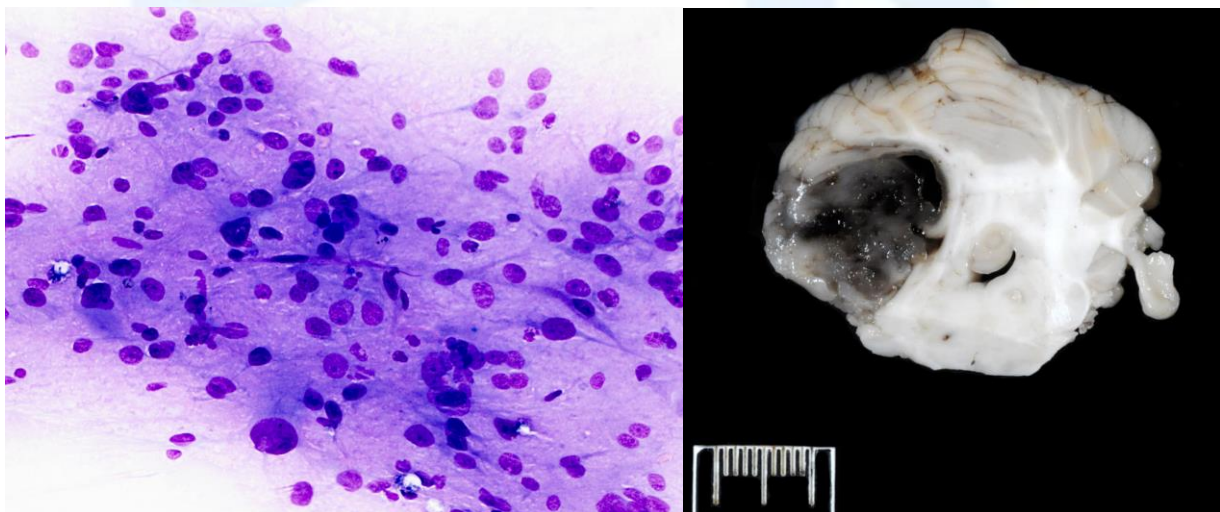
From The Davis-Thompson Foundation*

Case #: 99 Month: June Year: 2018

Contributors: Sarah E. Stevens, DVM, MS and Kevin Woolard, DVM, PhD, DACVP, School of Veterinary Medicine, University of California, Davis, CA 95616.

Clinical History: A dog presented to the Neurology service for evaluation of worsening vestibular signs. Approximately 1-2 weeks prior to presentation, she developed a left head tilt with intermittent episodes of horizontal nystagmus and then became ataxic. The night prior to presentation, she became acutely worse being unable to ambulate but remaining responsive. There was no history of toxin exposure or prior illness. The patient was non-ambulatory on presentation with severe right-sided torticollis, positional nystagmus including rotary, vertical and horizontal with fast phase to the left, and delayed to absent conscious proprioception with neuroanatomical localization to right-sided central vestibular. Due to severity of clinical signs and poor prognosis, euthanasia was elected with post mortem examination. Clinical hematology and biochemistry were unremarkable. On necropsy, the predominant finding was a focal, approximately 1.5 cm diameter, well demarcated, soft, nodular mass that was mottled grey to dark red to black expanding the right aspect of the cerebellum.

Cytology and gross images:



Follow up question: differential diagnoses?

*The Diagnostic Exercises are an initiative of the **Latin Comparative Pathology Group (LCPG)**, the Latin American subdivision of The Davis-Thompson Foundation. These exercises are contributed by members and non-members from any country of residence. Consider submitting an exercise! A final document containing this material with answers and a brief discussion will be posted on the CL Davis website (http://www.cldavis.org/diagnostic_exercises.html).

Associate Editor for this Diagnostic Exercise: Patricia Pesavento

Editor-in-chief: Vinicius Carreira