



Diagnostic Exercise

From The Davis-Thompson Foundation*

Case #: 94 Month: April Year: 2018

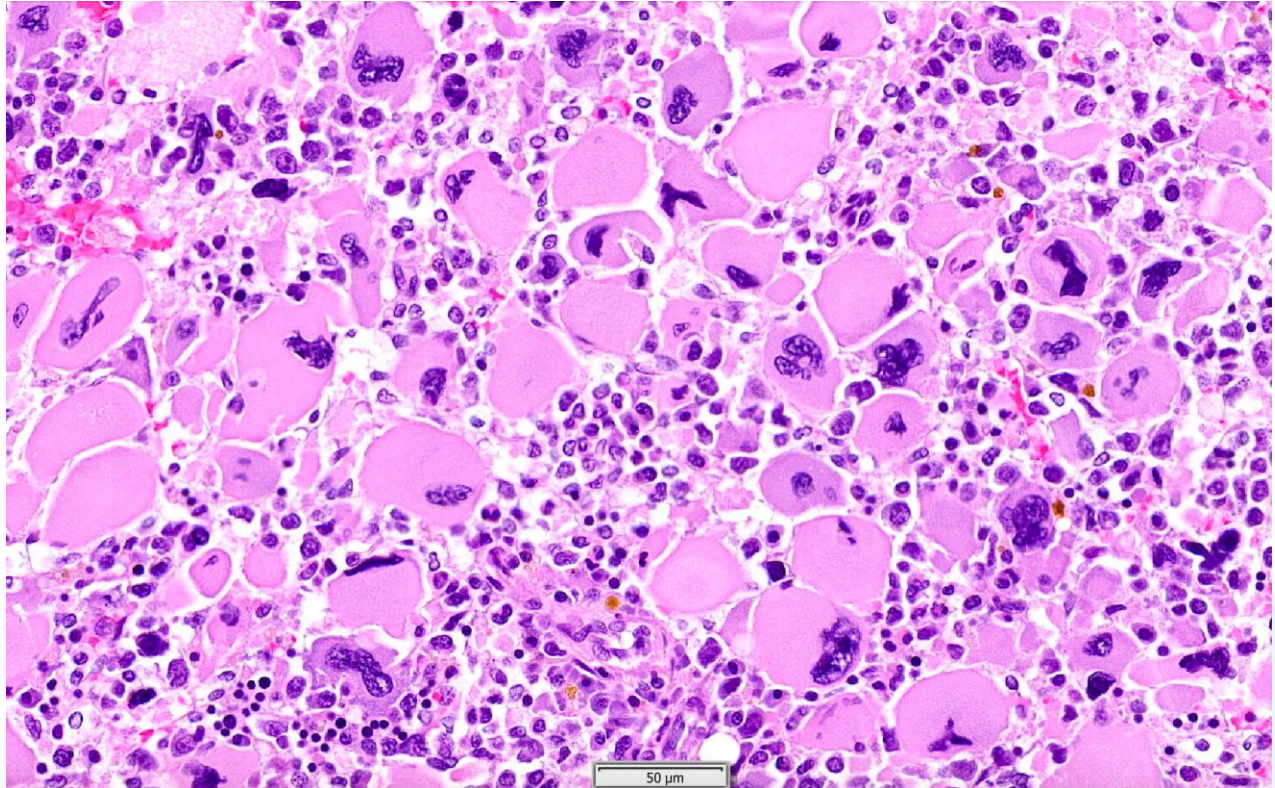
Contributors: Wesley Siniard, DVM Anatomic Pathology Resident Zoo/Wildlife Track; Peter Moore, DVM, PhD; Bill Vernau, BSc, BVMS, DVSc, PhD; School of Veterinary Medicine, University of California, Davis and William R. Pritchard Veterinary Medical Teaching Hospital, Davis, CA 95616.

Clinical History: 10-year-old, male castrated Shetland Sheepdog. The dog originally presented in October of 2016 for a C1-C5 myelopathy and poly-arthritis. He then presented in late November for progressive lameness and muscle atrophy along with a two-week history of inappetance. A complete blood count was performed and a marked macrocytic, hypochromic, non-regenerative anemia was noted. Multiple tests were performed but a cause for the anemia was not identified. He was sent home on pain medications, and close monitoring of his red blood cell counts were recommended. In mid-January of 2017, he was transferred from the referring veterinarian for a blood transfusion. A complete blood count and blood smear revealed progression of the anemia along with a leukopenia. Unclassified cells were present along with rare myelocytes and giant bizarre platelets. Due to poor prognosis and financial constraints, euthanasia was elected.

Laboratory Findings: Macrocytic, hypochromic, non-regenerative anemia. Joint tap: Marked suppurative inflammation but culture negative (potential immune-mediated polyarthritis (IMPA)).

Necropsy Findings: Moderate to severe, diffuse atrophy of all skeletal muscles was present. All mucous membranes and internal tissues exhibited severe pallor. The bone marrow (illustrated below) in all long bones as well as vertebrae was diffusely dark red.

Microscopic Image:



Follow-Up Questions: Morphologic Diagnosis, immunohistochemistry profile, disease.

*The Diagnostic Exercises are an initiative of the **Latin Comparative Pathology Group (LCPG)**, the Latin American subdivision of The Davis-Thompson Foundation. These exercises are contributed by members and non-members from any country of residence. Consider submitting an exercise! A final document containing this material with answers and a brief discussion will be posted on the CL Davis website (http://www.cldavis.org/diagnostic_exercises.html).

Associate Editor for this Diagnostic Exercise: Patricia Pesavento

Editor-in-chief: Vinicius Carreira