

Diagnostic Exercise

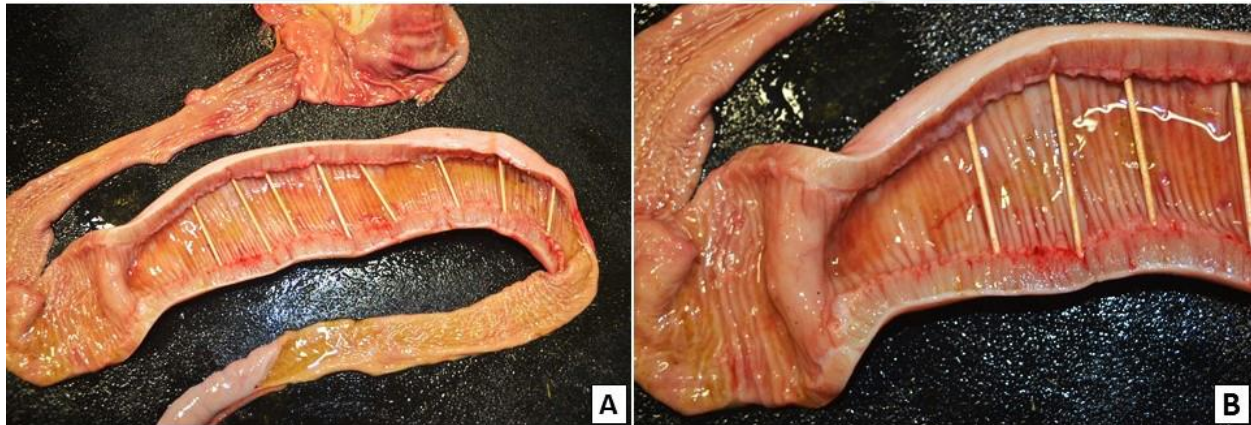
From The Davis-Thompson Foundation*

Case #: 83 Month: Aug Year: 2017

Contributor: Yianelly Rodriguez Ruiz¹; Tatiane Terumi Negrão Watanabe², DVM, MS, PhD; Ingeborg M. Langohr², BS, DVM, MS, PhD, DACVP. ¹Tuskegee University College of Veterinary Medicine, Tuskegee, AL 36088. ²Louisiana State University College of Veterinary Medicine, Department of Pathobiological Sciences and Louisiana Animal Disease Diagnostic Laboratory, Baton Rouge, LA 70803.

Clinical history, laboratory and necropsy findings: A 10-year-old American Miniature gelding presented for evaluation of being down and unable to rise. The horse had muscle atrophy on both fore and hind limbs, inability to rise, tachycardia, tachypnea, and dehydration. Mild gas distention of the small intestine was observed on abdominal radiographs. An intussusception of the small intestine or the ileocecal junction was suspected based on abdominal ultrasound. Due to poor prognosis, euthanasia was elected and the horse was submitted for post-mortem examination.

Necropsy Findings:



Follow-up questions: Description of necropsy findings; morphologic diagnosis; possible associated lesions.

*The Diagnostic Exercises are an initiative of the **Latin Comparative Pathology Group (LCPG)**, the Latin American subdivision of The Davis-Thompson Foundation. These exercises are contributed by members and non-members from any country of residence. Consider submitting an exercise! A final document containing this material with answers and a brief discussion will be posted on the CL Davis website (http://www.cldavis.org/diagnostic_exercises.html).

Associate Editor for this Diagnostic Exercise: Ingeborg Langohr

Editor-in-chief: Vinicius Carreira

GPCCOL

