



# Diagnostic Exercise

## From The Davis-Thompson Foundation\*

Case #: 79 Month: April Year: 2017

**Contributors:** Mauricio Navarro, DVM, MSc, PhD candidate in Integrative Pathobiology and Francisco Uzal, DVM, MSc, PhD, DipACVP, California Animal Health and Food Safety Laboratory, San Bernardino Branch, University of California, Davis.

**Clinical History:** 4-year-old Hereford cow found dead.

**Necropsy findings:**

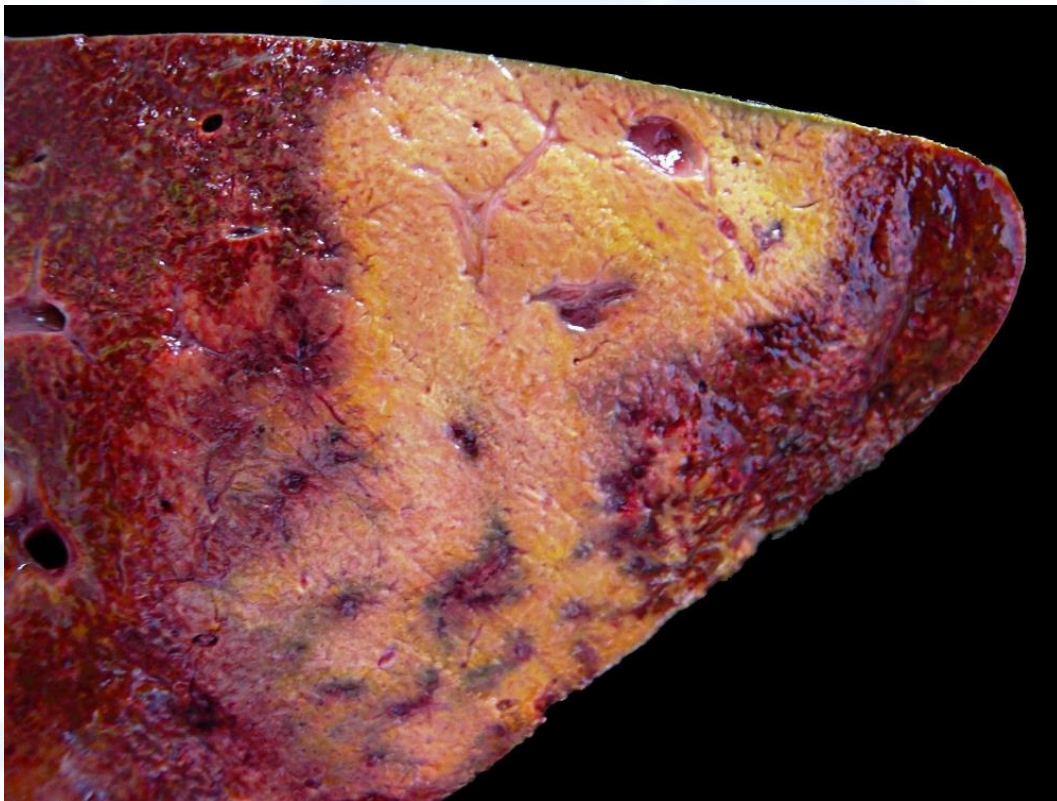
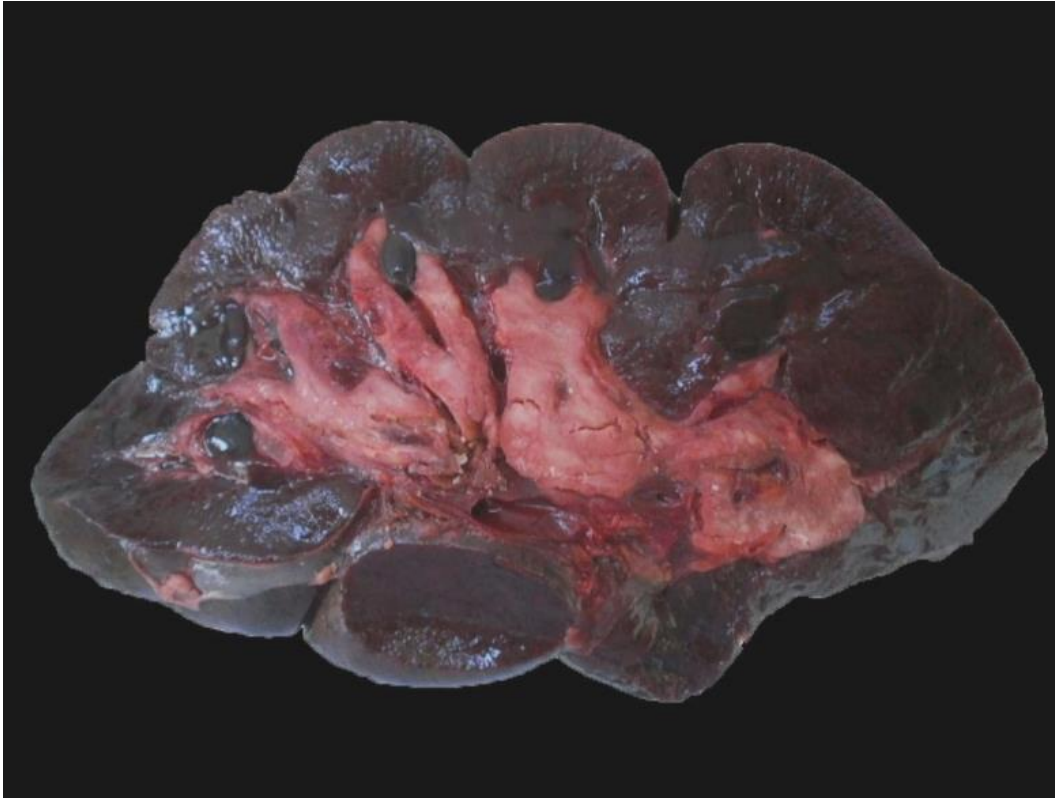

Figure 1.



**Figure 2.**

**Follow-up questions:** Description of the macroscopic and microscopic findings, morphologic diagnoses, name the disease, etiology, name the main predisposing factor, and pathogenesis.

\*The Diagnostic Exercises are an initiative of the **Latin Comparative Pathology Group (LCPG)**, the Latin American subdivision of The Davis-Thompson Foundation. These exercises are contributed by members and non-members from any country of residence. Consider submitting an exercise! A final document containing this material with answers and a brief discussion will be posted on the CL Davis website ([http://www.cldavis.org/diagnostic\\_exercises.html](http://www.cldavis.org/diagnostic_exercises.html)).

**Associate Editor for this Diagnostic Exercise:** Francisco Uzal

**Editor-in-chief:** Vinicius Carreira