

# Diagnostic Exercise

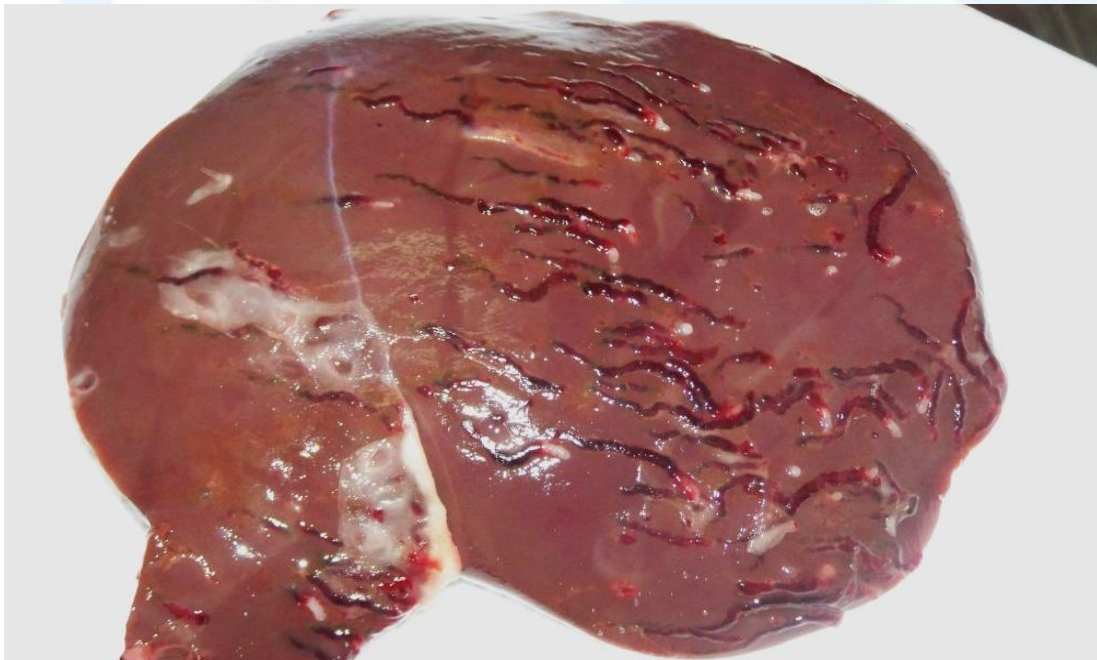
## From The Davis-Thompson Foundation\*

**Case #: 68 Month: May Year: 2016**

**Contributors:** W. Roger Kelly, Assoc. Prof. Veterinary Pathology (retired), University of Queensland, Australia, Veterinary School and Dr. Patrick Staples Veterinary Pathologist; NSW State Veterinary Diagnostic Laboratory EMAI.

**Clinical History:** Specimen from an 8-month-old lamb brought to the Lavington (New South Wales) district veterinarian by a farmer, who reported that a number in the flock were losing weight. This was the most ill animal; it was found moribund and was euthanized and submitted for necropsy.

**Necropsy Findings:** Please see the image below.



**Follow up questions:** Morphologic diagnosis, most likely etiology, and steps you would follow to establish etiological diagnosis.

\*The Diagnostic Exercises are an initiative of the **Latin Comparative Pathology Group (LCPG)**, the Latin American subdivision of The Davis-Thompson Foundation. These exercises are contributed by members and non-members from any country of residence. Consider submitting an exercise! A final document containing this material with answers and a brief discussion will be posted on the CL Davis website ([http://www.cldavis.org/diag\\_exercise.html](http://www.cldavis.org/diag_exercise.html)).

**Associate Editor for this Diagnostic Exercise:** Francisco Uzal  
**Editor-in-chief:** Vinicius Carreira