

Diagnostic Exercise

From The Davis-Thompson Foundation*

Case #: 64 Month: January Year: 2016

Contributors: Camila Costa Abreu,¹ DVM, MSc, PhD student and Francisco A. Uzal,² DVM, MSc, PhD, DACVP. 1-Federal University of Lavras, Lavras, Minas Gerais, Brazil; 2-University of California, San Bernardino, California, US.

Clinical History: One of four, six-month-old Hereford steers was submitted for necropsy. Clinical signs were observed in only this one animal, which became severely depressed, dyspneic and recumbent approximately eight hours before it died. The other three calves were found dead without clinical signs. The most striking gross changes were observed in the skeletal muscle (Figure 1) and heart (Figure 2).

Necropsy Findings:

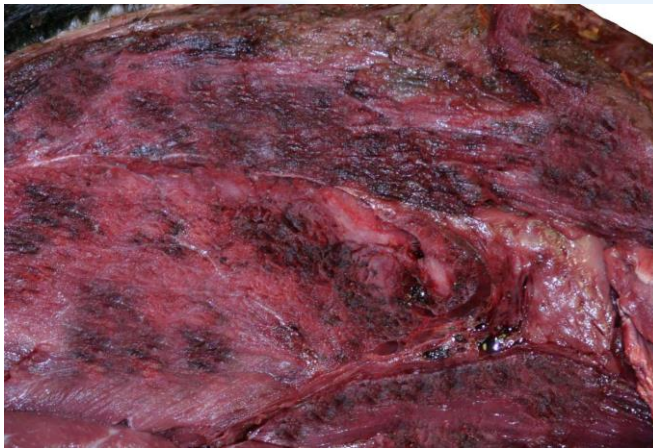

Figure 1

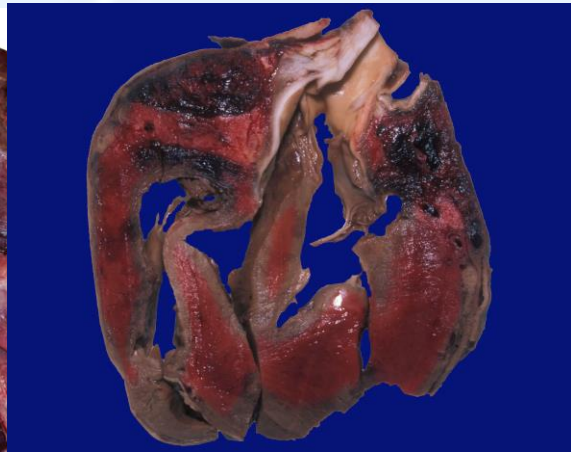


Figure 2

Morphologic diagnosis: Figure 1 - Myositis, necrotizing, acute, multifocal, severe; Figure 2 - myocarditis, necrotizing, acute, multifocal, severe.

Most likely etiology: *Clostridium chauvoei*

Histological features: Extensive multifocal areas of acute coagulative skeletal muscle and myocardial necrosis associated with interstitial edema, hemorrhage, fibrin deposition, mild inflammatory infiltrate (observed mostly in the periphery of the lesions) composed mostly of neutrophils, and large numbers of Gram positive rods, some with sub-terminal spores. Several arterioles show fibrinoid necrosis and are infiltrated by neutrophils. Large number of bacteria surrounded some of these blood vessels. The vascular lesions are more prominent in the myocardium.

Recommended diagnostic work up: Histology, anaerobic culture, fluorescent antibody test of muscle (skeletal and cardiac) smears for *C. chauvoei* (also other histotoxic clostridia to rule out other infections), immunohistochemistry of muscle (skeletal and cardiac) for *C. chauvoei* (also other histotoxic clostridia).

*The Diagnostic Exercises are an initiative of the **Latin Comparative Pathology Group (LCPG)**, the Latin American subdivision of The Davis-Thompson Foundation. These exercises are contributed by members and non-members from any country of residence. - Consider submitting an exercise! - A final document containing this material with answers and a brief discussion will be posted on the CL Davis website (http://www.cldavis.org/diagnostic_exercises.html).

Associate Editor for this Diagnostic Exercise: Francisco Uzal DVM PhD DACVP
Editor-in-chief: Vinicius Carreira, DVM PhD DACVP