



Diagnostic Exercise

From The Davis-Thompson Foundation*

Case #: 64 Month: January Year: 2016

Contributors: Camila Costa Abreu,¹ DVM, MSc, PhD student and Francisco A. Uzal,² DVM, MSc, PhD, DACVP. 1-Federal University of Lavras, Lavras, Minas Gerais, Brazil; 2-University of California, San Bernardino, California, US.

Clinical History: One of four, six-month-old Hereford steers was submitted for necropsy. Clinical signs were observed in only this one animal, which became severely depressed, dyspneic and recumbent approximately eight hours before it died. The other three calves were found dead without clinical signs. The most striking gross changes were observed in the skeletal muscle (Figure 1) and heart (Figure 2).

Necropsy Findings:

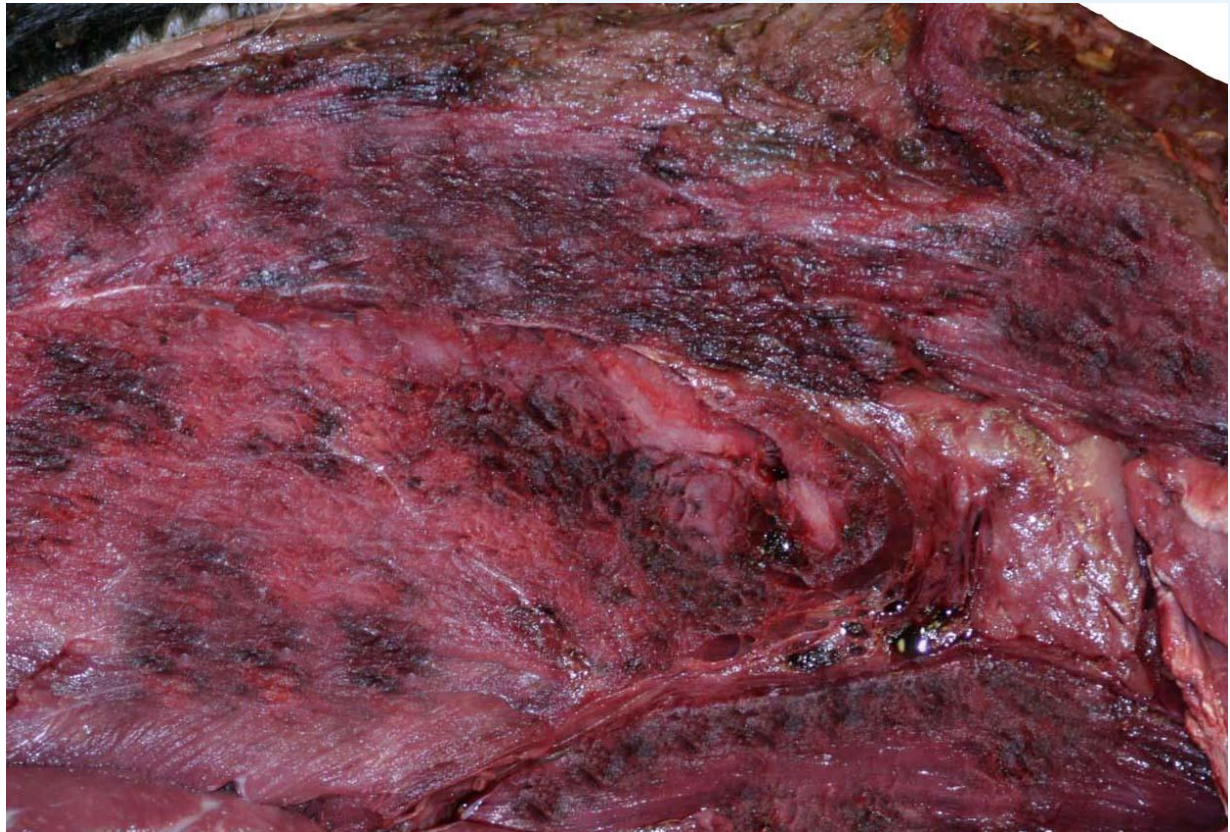

Figure 1

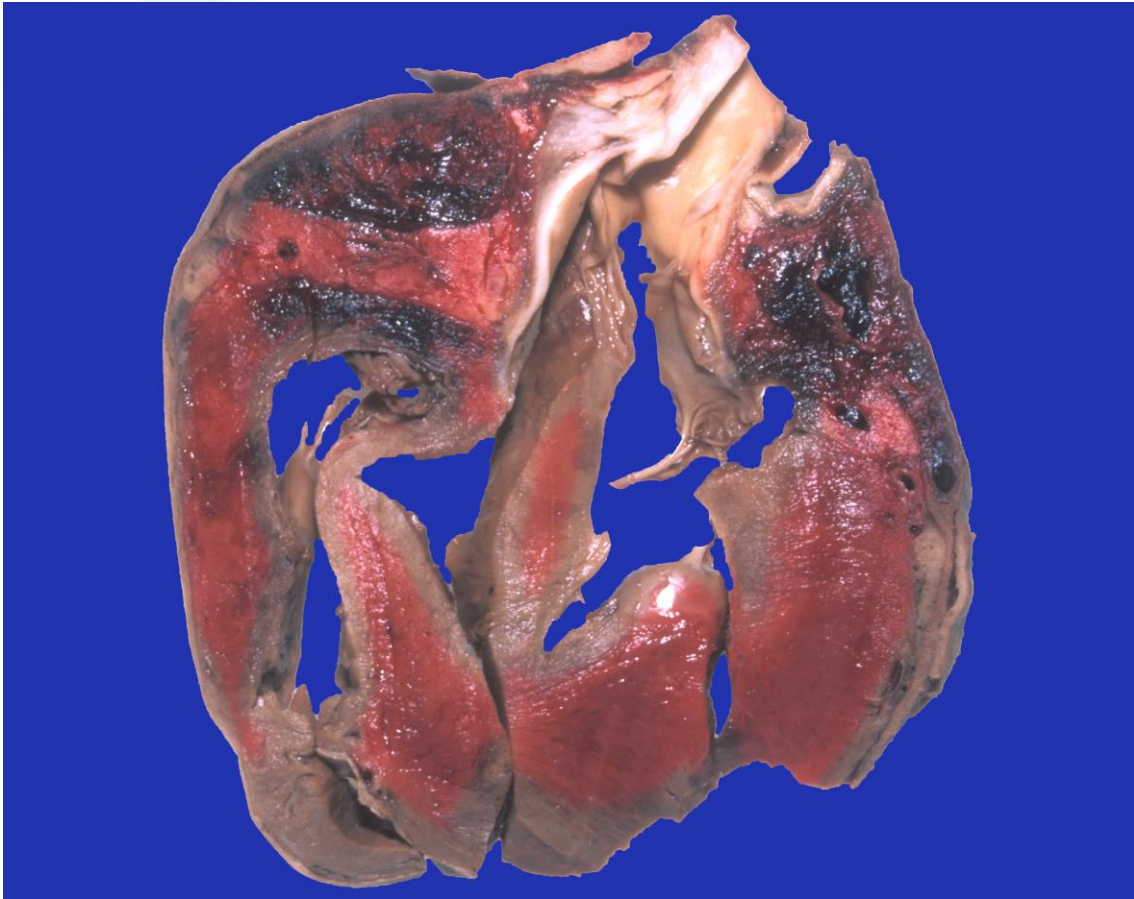


Figure 2

Follow-up questions: Morphologic diagnosis, most likely etiology, histological features, recommended diagnostic work up.

*The Diagnostic Exercises are an initiative of the **Latin Comparative Pathology Group (LCPG)**, the Latin American subdivision of The Davis-Thompson Foundation. These exercises are contributed by members and non-members from any country of residence. - Consider submitting an exercise! - A final document containing this material with answers and a brief discussion will be posted on the CL Davis website (http://www.cldavis.org/diagnostic_exercises.html).

Associate Editor for this Diagnostic Exercise: Francisco Uzal, DVM PhD DACVP

Editor-in-chief: Vinicius Carreira, DVM PhD DACVP