



Latin Comparative Pathology Group

The Latin Subdivision of the CL Davis Foundation

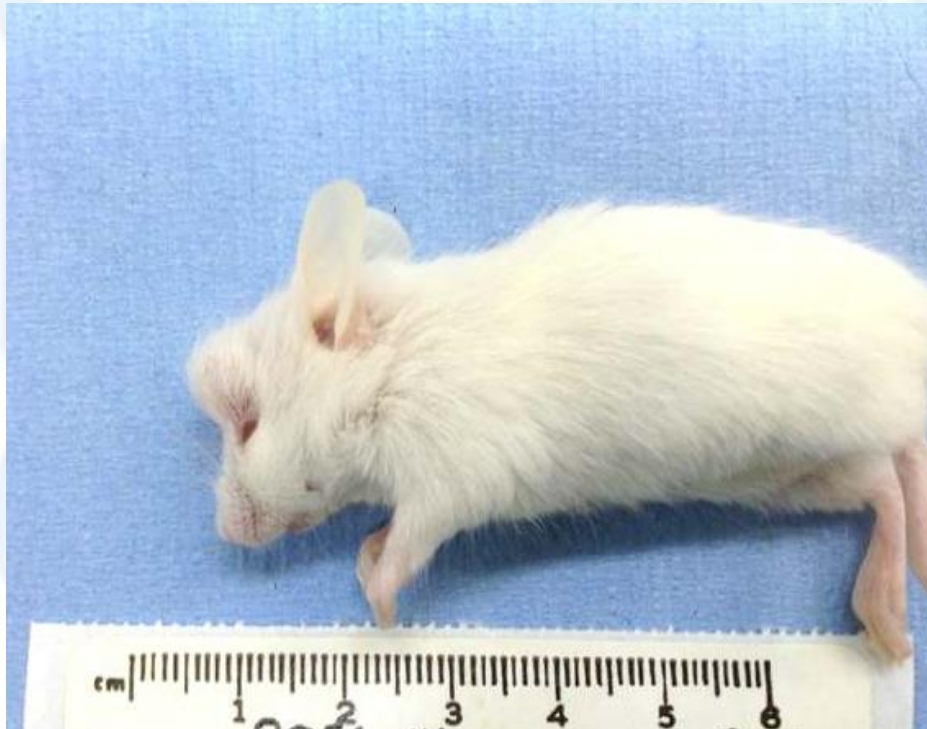
Diagnostic Exercise

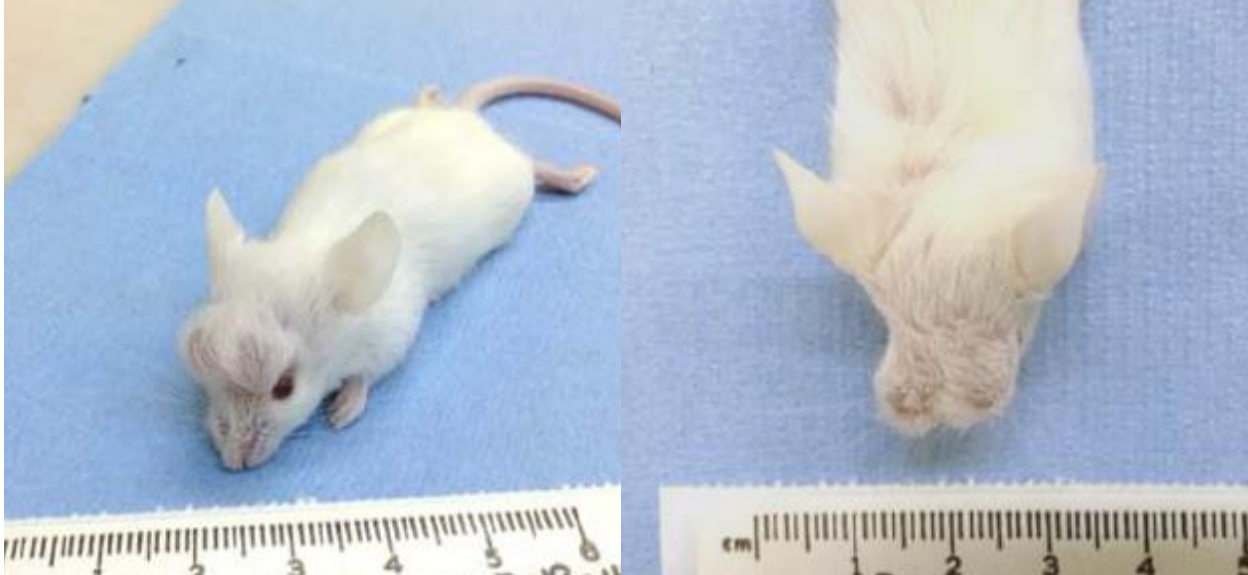
Case #: 50 Month: November Year: 2014

Contributor: M. Kelly Keating, DVM, DACVP, Case courtesy of the Comparative Pathology Laboratory, University of California-Davis, CA.

Clinical History: A 1-month-old Lhx6^{icre} mouse on Balb/c strain background presented with apparently non-painful swellings on the head, but otherwise bright, alert, and within normal limits.

Necropsy Findings:





Follow-up questions:

1. Description
2. Differential diagnoses
3. Histologic features of possible differential diagnoses

Please send your comments/questions to the whole LCPG list by hitting "reply to all".

A final document containing this material with answers and a brief discussion will be posted on the C. L. Davis website by the end of the current month (http://www.cldavis.org/lcpg_english.html).