



Latin Comparative Pathology Group

The Latin Subdivision of the CL Davis Foundation

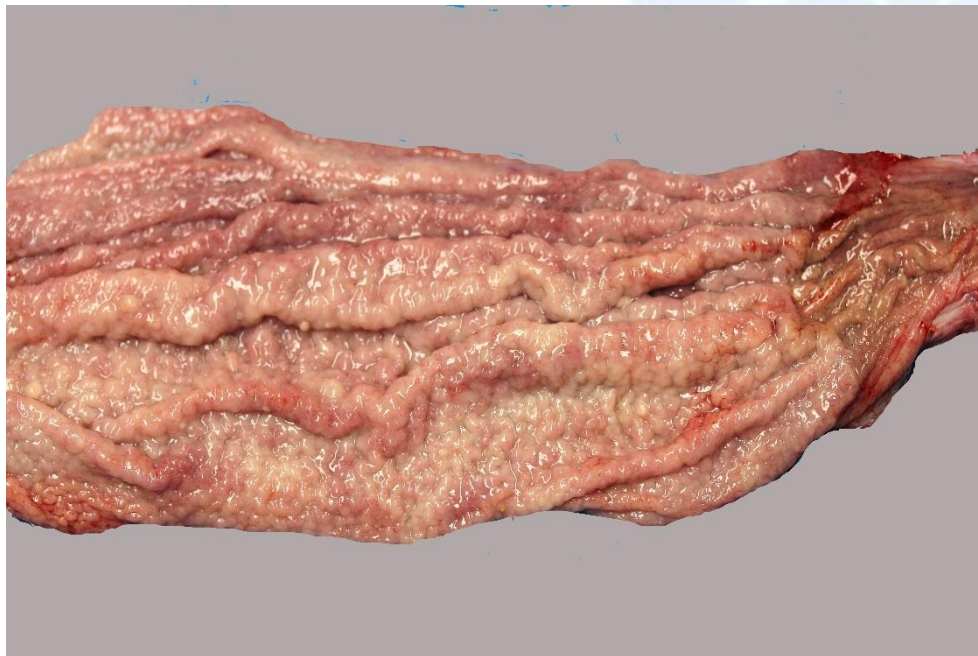
Diagnostic Exercise

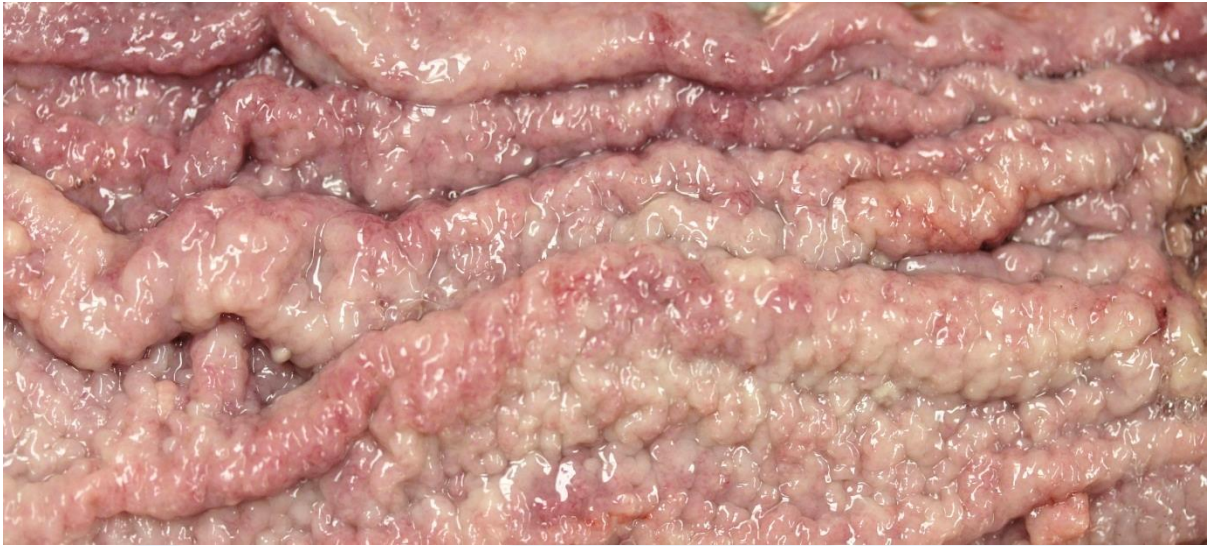Case #: 40 Month: January Year: 2014

Contributor: Panayiotis Loukopoulos¹ DVM, PGDipVSt, PhD; Serena Brenner² DVM; Santiago S. Diab¹ DVM, DACVP; Jorge P. Garcia¹ DVM; Francisco A. Uzal¹ DVM, MVSc, PhD, DACVP. ¹ California Animal Health and Food Safety laboratory, San Bernardino branch, University of California Davis, ² Lindsay Wildlife Museum, Walnut Creek, California.

Clinical History: A 20 year old, 1.70 kg, 1.88 cm long, female Pacific gopher snake (*Pituophis catenifer*) was presented to the California Animal Health and Food Safety laboratory (CAHFS) in San Bernardino for a full diagnostic work-up. The snake had been housed at a non-for-profit museum in California where it was occasionally handled by the public. It had a history of recurrent mid-coelomic swelling. Cryptosporidia were detected in the feces on repeated testing and it was euthanized due to epizootic concerns and concerns for the other animals in the collection.

Necropsy Findings: Please see the image below.





Follow-up questions: Macroscopic description, morphologic diagnosis, etiologic diagnosis, etiology, likely histologic findings.

Please send your comments/questions to the whole LCPG list by hitting "reply to all".

A final document containing this material with answers and a brief discussion will be posted on the C. L. Davis website by the end of the current month (http://www.cldavis.org/lcpg_english.html).