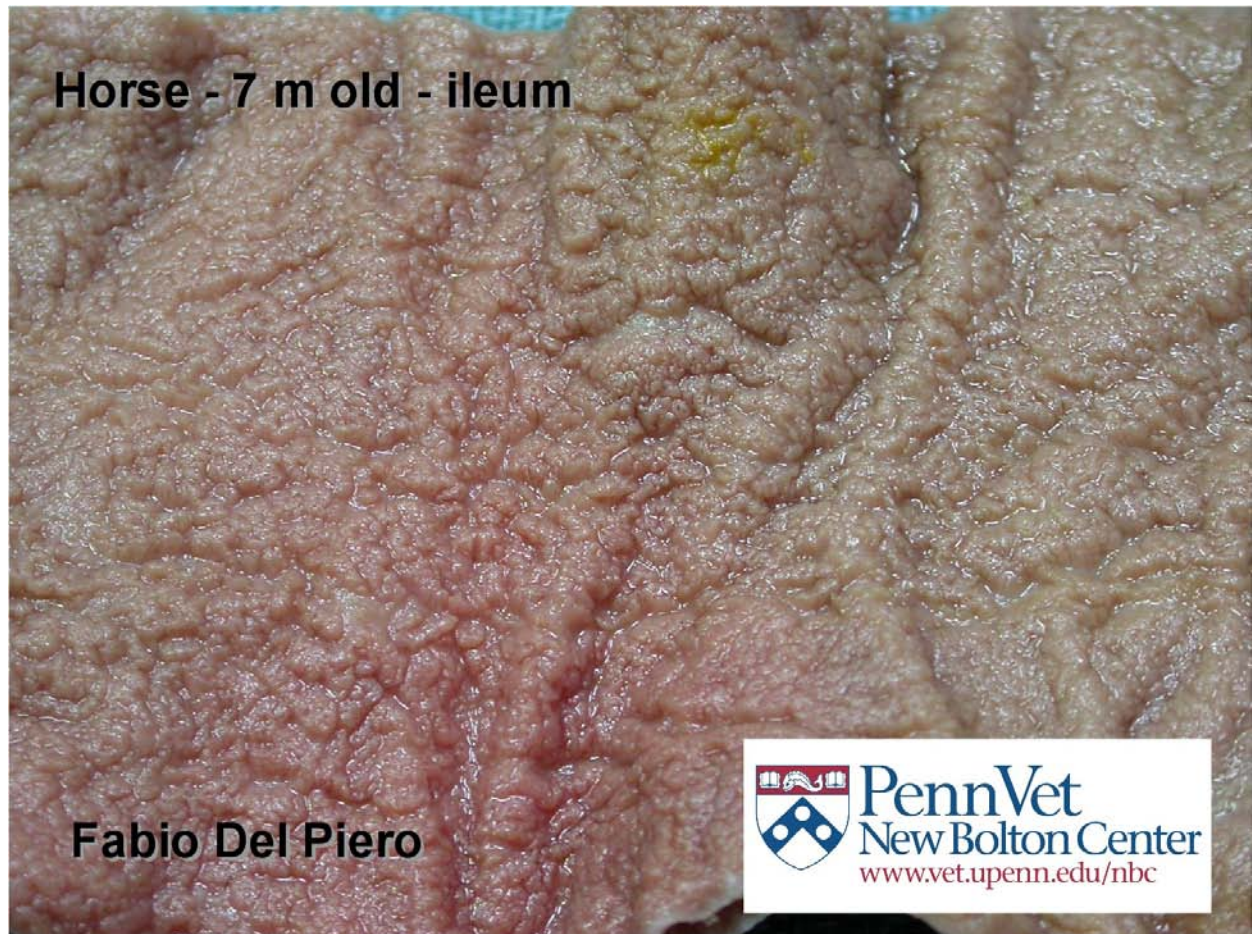
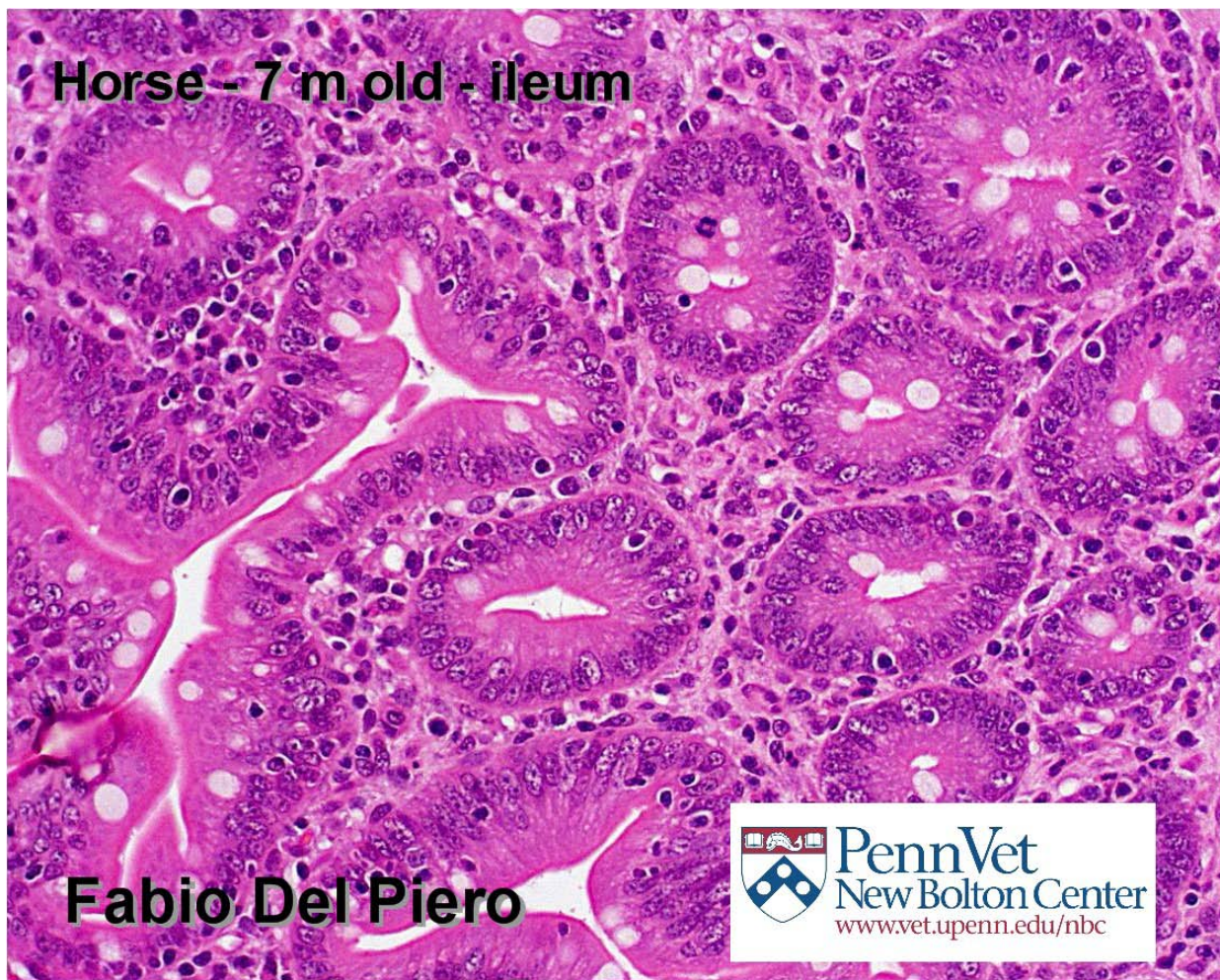


LCGP DIAGNOSTIC EXERCISE # 2 (August 2010)


Contributor: Fabio del Piero, New Bolton Center, University of Pennsylvania




Horse - 7 m old - ileum



Fabio Del Piero



Fabio Del Piero



Horse - 7 m old - ileum - Warthin - Starry stain

Please provide:

Gross: 1. Describe. 2. Differential morphologic diagnoses based on gross findings.

Histology: 1. Describe. 2. Morphologic diagnosis.

Warthin Starry stain. 1. Describe.

Etiologic Diagnosis.

Please send your comments/answers to the whole LCGP list, or individually to me at:

fuzal@cahfs.ucdavis.edu

I will post Dr Del Piero's answers to these questions together with a summary of the comments I receive from our members in a couple of weeks, at our website:
http://www.cldavis.org/lcpg_english.html