



Diagnostic Exercise From The Davis-Thompson Foundation*

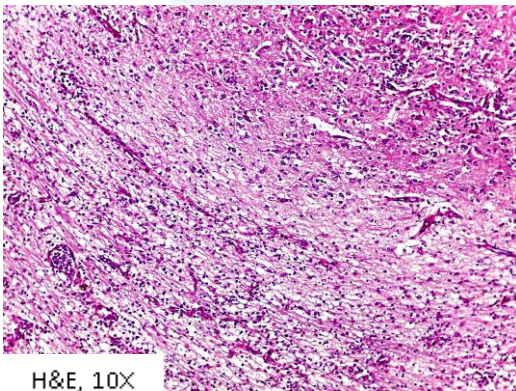
Case #: 147 Month: August Year: 2020

Contributors: Gabriela C. Postma, DVM, PhD; Leonardo Minatel, DVM, PhD.
Universidad de Buenos Aires, Argentina.

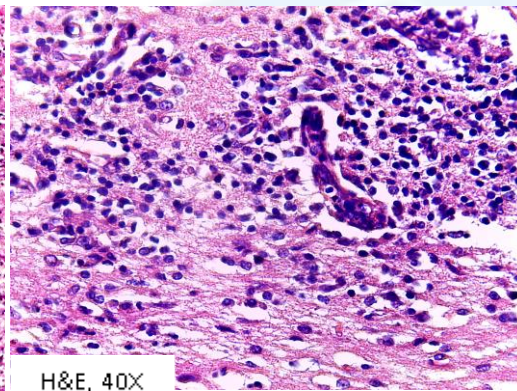
Clinical History: A one-month-old female puppy was submitted for necropsy to the Pathology Veterinary Service of Buenos Aires University, Argentina. The clinical history was provided by the referring veterinarian. A pregnant stray bitch, with her litter of six puppies, was adopted from the street. One puppy died at the age of one month, presumably due to cranial trauma; it was not examined. Three other puppies became ill, showing neurologic signs. Clinical signs included reduced appetite, depression, constant crying, weight loss, weakness, convulsions and recumbency. Two of the sick puppies died spontaneously, one of which was submitted for necropsy.

Necropsy Findings: Grossly, the carcass was icteric with an orange liver and moderate splenomegaly. No other gross lesions were observed.

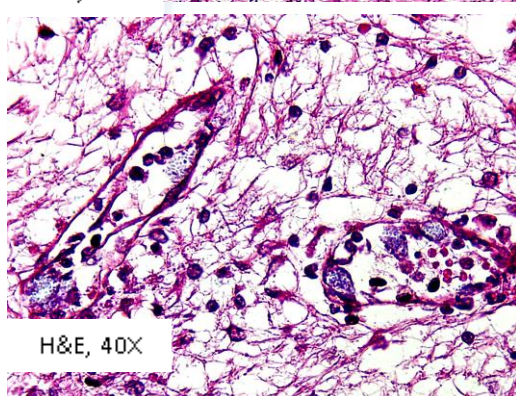
Histological Findings



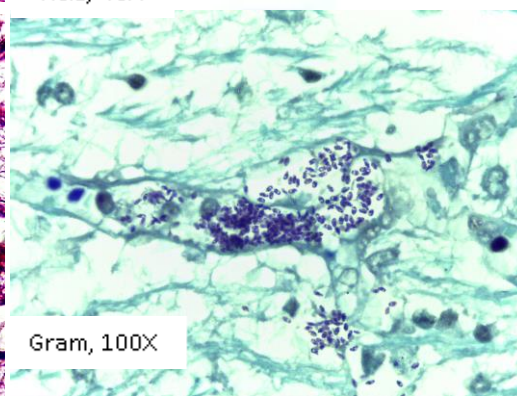
H&E, 10X



H&E, 40X



H&E, 40X



Gram, 100X

Follow-up questions:

- 1) Histological description;
- 2) Morphologic diagnosis;
- 3) Etiology.

Editor-in-chief: Claudio Barros

Associate Editor for this Diagnostic Exercise: Mariano Carossino