



Diagnostic Exercise

From The Davis-Thompson Foundation*

Case #: 119 Month: April Year: 2019

Contributors: Alan T. Loynachan, DVM, PhD, Dip. ACVP, University of Kentucky Veterinary Diagnostic Laboratory. Lexington, KY.

Clinical History: A 9-year-old, Warmblood gelding was euthanized following a 6-week history of chronic weight loss, coughing, intermittent fever, lethargy, and anorexia.

Laboratory Findings: Fibrinogen= 1000 mg/dl; WBC= 6,000 cells/ μ l (80% segmented neutrophils).

Necropsy Findings: Discrete, multifocal to coalescing, firm nodules, which ranged from 1 cm in diameter up to 16 x 13 x 7 cm, elevated the visceral pleura and expanded the parenchyma of all lung lobes. On cut surface, the nodules were tan, solid and firm, and slightly bulged on cut surface. The left and right lung lobes weighed 10.43 and 9.53 kg, respectively; as reference, normal adult equine lung lobes weigh approximately 3 kg (left lung lobe) and 3.5 kg (right lung lobe). The bronchial lymph nodes were enlarged (2-4X) and edematous.

Gross and/or Microscopic Images:

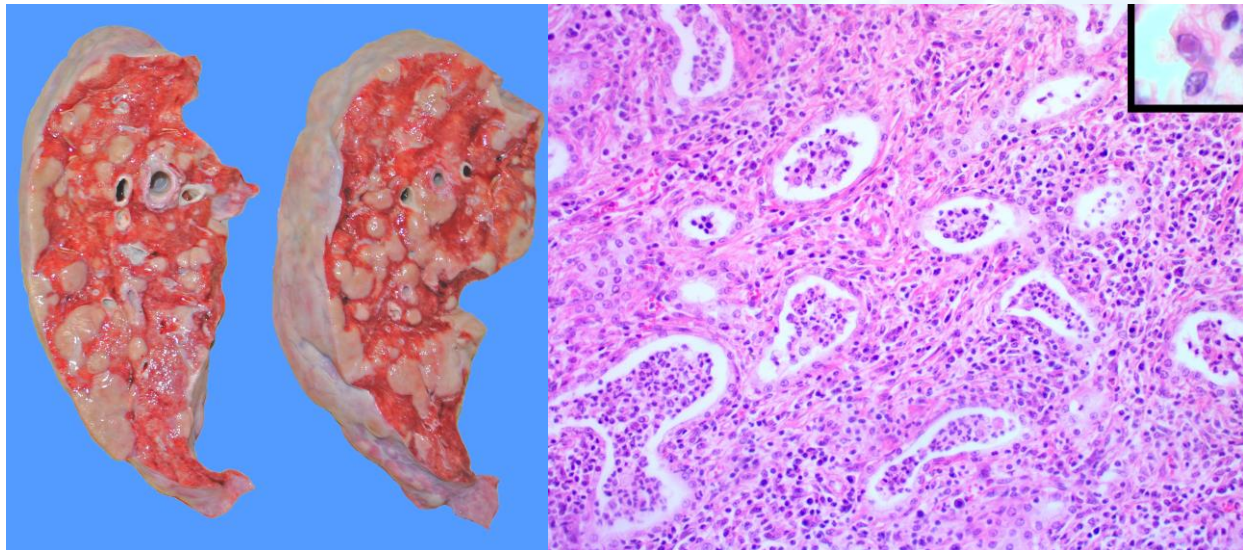


Figure 1 (left) - Right lung lobe, cut surface. Figure 2 (right) - Lung, 20X. Inset 60X. Hematoxylin and eosin.

Follow-up Questions: Provide a morphologic diagnosis, name the disease, what infectious microorganism has been associated with this disease?

*The Diagnostic Exercises are an initiative of the **Latin Comparative Pathology Group (LCPG)**, the Latin American subdivision of The Davis-Thompson Foundation. These exercises are contributed by members and non-members from any country of residence. Consider submitting an exercise! A final document containing this material with answers and a brief discussion will be posted on the CL Davis website (http://www.cldavis.org/diagnostic_exercises.html).

Associate Editor for this Diagnostic Exercise: Mariano Carossino
Editor-in-chief: Vinicius Carreira