



Diagnostic Exercise

From The Davis-Thompson Foundation*

Case #: 110 Month: December Year: 2018

Answer Sheet

Title: Hepatic and renal lipidoses in a female donkey.

Contributors: José Cesar Menk Pinto Lima^{1,2}, DVM; Tatiane Terumi Negrão Watanabe², DVM, MS, PhD; Shannon Connard³, BS, DVM; Heidi Banse³, BS, DVM, PhD, DACVIM; Ingeborg M. Langohr², BS, DVM, MS, PhD, DACVP

¹ Laboratório de Patologia Veterinária (LPAVET), Santo André, SP, Brazil; ² Louisiana State University School of Veterinary Medicine, Department of Pathobiological Sciences and Louisiana Animal Disease Diagnostic Laboratory, Baton Rouge, LA 70803; ³ Louisiana State University School of Veterinary Medicine, Department of Veterinary Clinical Sciences, Baton Rouge, LA 70803.

Gross Description: The liver is enlarged and has rounded margins, with pale tan and smooth capsular surface. The hepatic parenchyma is diffusely pale tan and friable. Both kidneys are similarly diffusely pale tan and very friable.

Morphologic Diagnoses: Liver and Kidneys: Lipidoses, diffuse, severe.

Condition: Hyperlipemia.

Microscopic Findings:

Liver - The hepatic parenchyma had diffuse lipid-type degeneration (Figure 3) characterized by hepatocytes containing single large or multiple smaller, clear, discrete cytoplasmic vacuoles that often displace the nuclei to the periphery (Figure 3; H&E, 5x. Inset; 20x). Small aggregates of macrophages and few neutrophils were randomly distributed throughout the degenerate hepatic parenchyma.

Kidney - Frequently the epithelial cells of the proximal convoluted tubules had variably sized, single, clear, discrete cytoplasmic vacuoles (Figure 4; H&E, 10x. Inset; 40x).

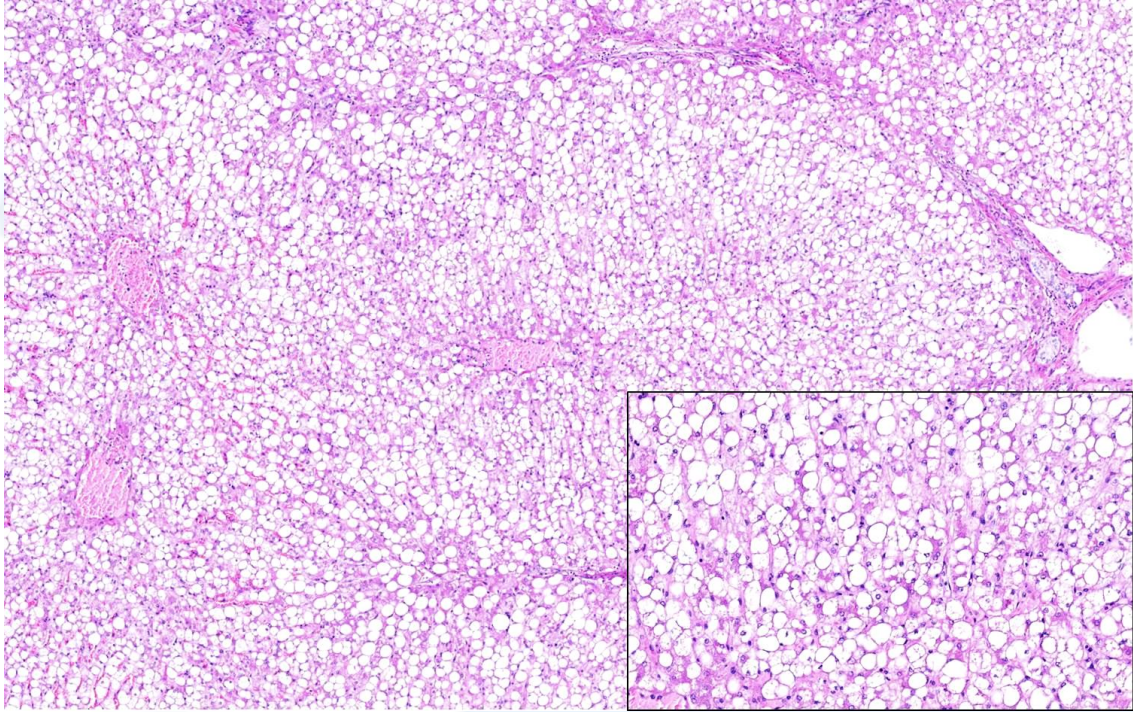


Figure 1

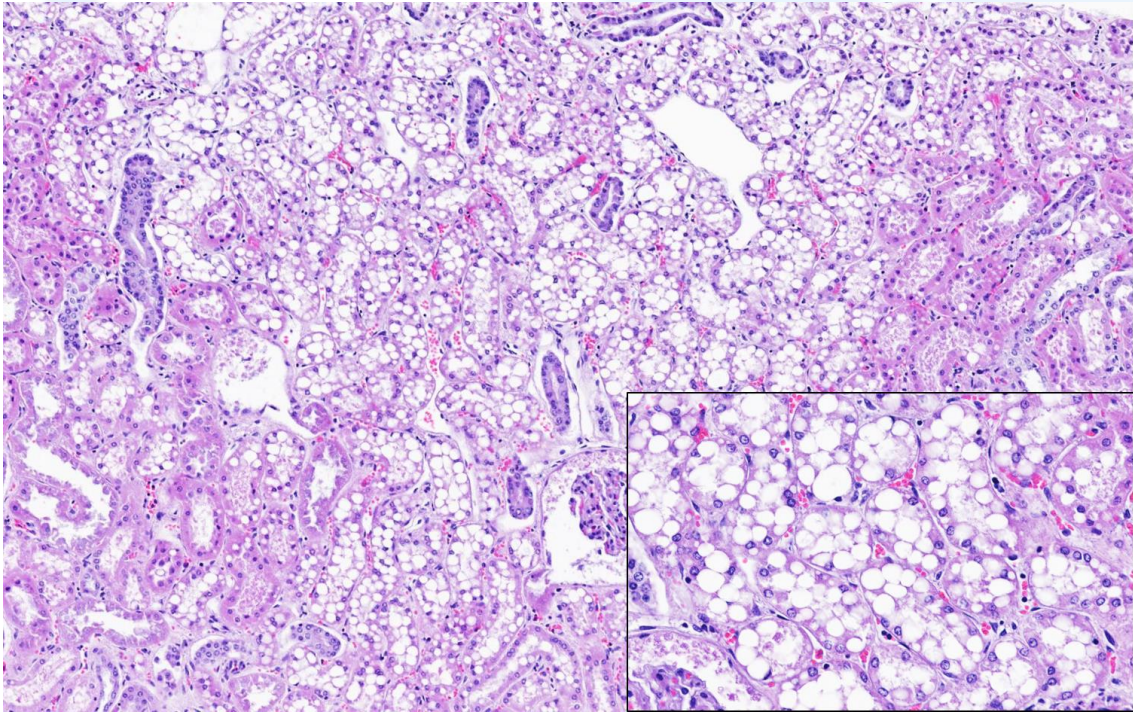


Figure 2

Discussion: Hyperlipemia is a metabolic disorder most commonly seen in ponies, miniature horses and donkeys. It is characterized by the abnormal accumulation of tryglicerides within hepatocytes (hepatic lipidosis) and results from

hepatic triglyceride synthesis exceeding the formation and release of very low density lipoprotein (VLDL) into circulation. Clinical signs include apathy and anorexia; hepatic encephalopathy can sometimes occur as well.^{1,3}

Hepatic lipidosis occurs in association with hyperlipidemia, which results from rapid mobilization of body fat in response to negative energy balance from primary (obesity, pregnancy, lactation) or secondary (systemic diseases) risk factors.^{1,2,6} Donkeys and ponies have been shown to be at greatest risk of developing hyperlipemia, with a prevalence of 3-5% in the general population and 11-18% in inpatient populations in veterinary hospitals, with mortality rates of 60-80% frequently reported.⁹ Impaired dental function or dental pain such as in the present case may render an individual inappetent, leading to excessive lipid mobilization from body storages, with fatty acids being transported to the liver, where this excess is deposited as intracellular droplets of triglycerides.^{2,5,8} Furthermore, conditions like pregnancy and lactation, plus the stress associated with treatment, can greatly increase the risk of developing hyperlipemia.^{2,3}

Grossly, the liver is enlarged, greasy, yellow to pale tan, and bulging on cut surface; if the liver enlargement is severe enough, the hepatic capsule can rupture.¹ Microscopically, there is diffuse enlargement of hepatocytes, which contain variably sized clear vacuoles, often displacing the nucleus peripherally.⁴ Other organs such as kidneys, heart, and skeletal muscle can also be involved.⁷

The diagnosis of hyperlipemia is based on history, demonstration of high levels of plasma triglycerides, and observation of compatible gross and histological findings.^{2,6} Special histological stains such as Sudan Black B and Oil Red O can help further demonstrating lipids in frozen sections.³

References and Recommended Literature:

1. Buergelt, C.D. and Del Piero, F. Lipidosis. In: __ Color Atlas of Equine Pathology. Wiley-Blackwell, New York, NY, 2014: 254-255.
2. Burden, F.A., Du Toit, N., Hazell-Smith, E., and Trawford, A.F. Hyperlipemia in a Population of Aged Donkeys: Description, Prevalence, and Potential Risk Factors. *J Vet Intern Med.* 2011; 25: 1420-1425.
3. Conwell, R. Hyperlipaemia in a Pregnant Mare with Suspected Masseter Myodegeneration. *Vet Record.* 2010; 166: 116-117.
4. Cullen, J.M. and Stalker, M.J. Liver and Biliary System. In: M.G. Maxie (ed). *Jubb, Kennedy, and Palmer's Pathology of Domestic Animals.* 6th ed. Elsevier; 2016, vol. 2, 258-352.

5. Grove, V. Hyperlipaemia. In: E.D. Svendsen (ed). The Professional Handbook of the Donkey, 4th ed. Grove V. London: Whittet Books Ltd; 2008: 52-61.
6. Moore, B.R., Abood, S.K., and Hinchcliff, K.W. Hyperlipemia in 9 Miniature Horses and Miniature Donkeys. J Vet Intern Med. 1994; 8: 376-381
7. Myers, R.K., McGavin, M.D. and Zachary, J.F. Cellular Adaptations, Injury, and Death: Morphologic, Biomechanical, and Genetic Bases. In: M.D. McGavin and J.F. Zachary (eds). Pathologic Basis of Veterinary Disease. 5th ed. Rio de Janeiro, RJ, Brazil (translated); Elsevier; 2013: 32-34.
8. Palmer, M.V. and Olsen, S.C. Hepatic Lipidosis in Pregnant Captive American Bison (*Bison bison*). J Vet Diagn Invest. 2002; 14: 512-515.
9. Watson, T. Equine hyperlipemia. In: __ Metabolic and Endocrine Problems of the Horse. London: WB Saunders; 1998: 23-40.

*The Diagnostic Exercises are an initiative of the **Latin Comparative Pathology Group (LCPG)**, the Latin American subdivision of The Davis-Thompson Foundation. These exercises are contributed by members and non-members from any country of residence. Consider submitting an exercise! A final document containing this material with answers and a brief discussion will be posted on the CL Davis website (http://www.cldavis.org/diagnostic_exercises.html).

Associate Editor for this Diagnostic Exercise: Ingeborg Langohr

Editor-in-chief: Vinicius Carreira