



Diagnostic Exercise

From The Davis-Thompson Foundation*

Case #: 109 Month: November Year: 2018

Contributor: Erin K. Morris, DVM, Diplomate ACVP. WRAIR-NMRC. Forest-Glen Annex, MD.

Clinical History: This was an incidental finding in an 11-week-old Sprague-Dawley QA/QC rat.

Necropsy Findings: There were no gross lesions reported on necropsy.

Microscopic Image:

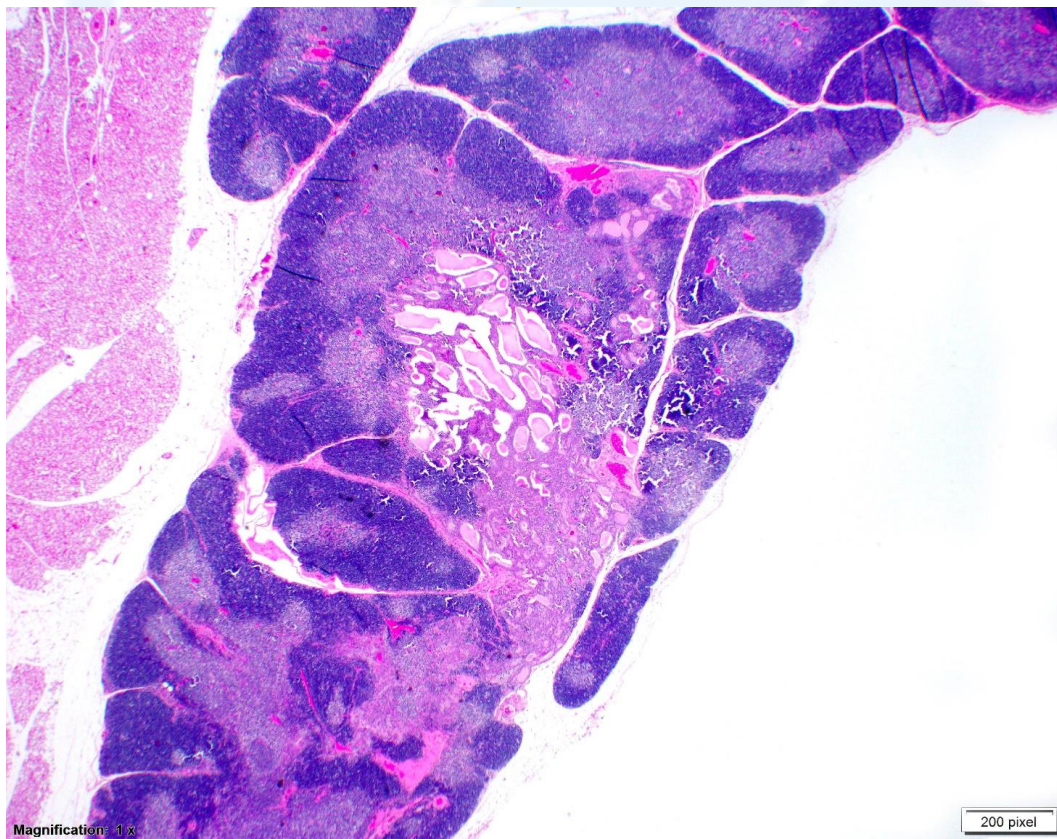


Figure 1. H&E stain, 20X

Follow-up Questions: Please provide tissue identification, morphologic diagnosis, and differential diagnosis(es).

*The Diagnostic Exercises are an initiative of the **Latin Comparative Pathology Group (LCPG)**, the Latin American subdivision of The Davis-Thompson Foundation. These exercises are contributed by members and non-members from any country of residence. Consider submitting an exercise! A final document containing this material with answers and a brief discussion will be posted on the CL Davis website (http://www.cldavis.org/diagnostic_exercises.html).

Associate Editor for this Diagnostic Exercise: Ingeborg Langohr

Editor-in-chief: Vinicius Carreira