



Latin Comparative Pathology Group

The Latin Subdivision of the CL Davis Foundation

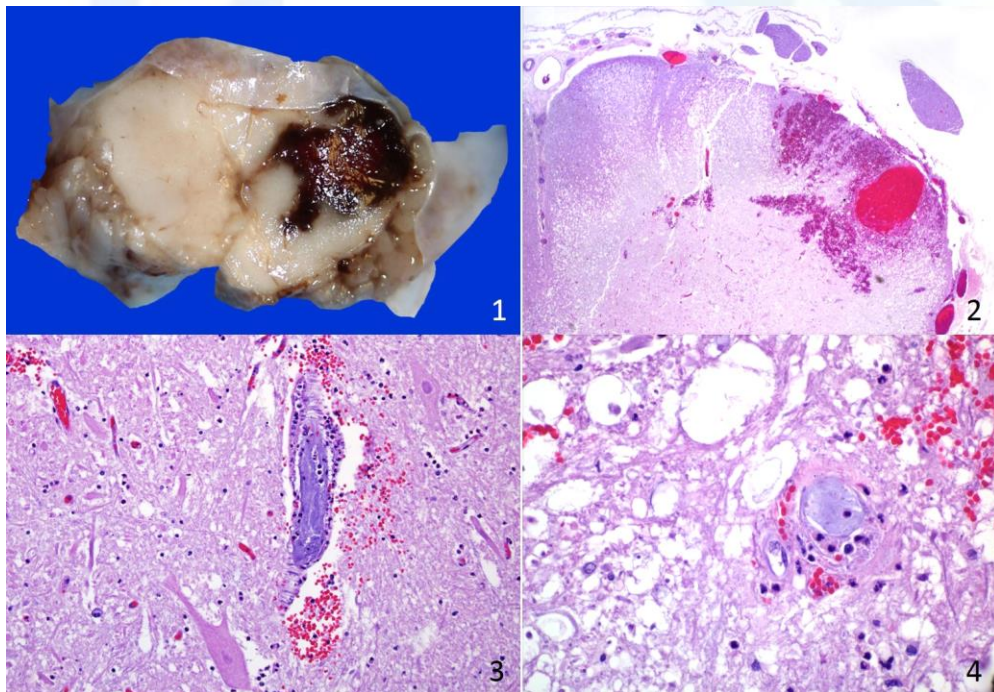
Diagnostic Exercise

LCPG Case #: 100 Month: July Year: 2018

Contributor: Francisco R Carvallo, MV, DSc, Dipl. ACVP. – California Animal Health and Food Safety Laboratory, San Bernardino branch. 105 W Central Ave, San Bernardino, CA 92408.

Clinical History: A 15-year-old male Potbelly pig had a history of loss of control of the back legs, not being able to empty the bladder, and constipation. Due to poor prognosis and no response to treatment, the pig was euthanized and submitted for necropsy.

Macroscopic Exam: The carcass was in good body condition. The pressure points of the skin of the hind limbs had focal areas of congestion and hemorrhages. The trachea contained small amounts of white stable foam. The lungs were diffusely red and wet. In the abdomen, there were approximately 500 ml of transparent fluid. The urinary bladder was markedly distended and had focal hemorrhages along the serosa. The cecum, colon and rectum were dilated with firm pelletized feces and the mucosa was congested with a reticular pattern. Other internal organs were unremarkable. The brain and spinal cord were removed and analyzed. Mild degeneration and protrusion of few intervertebral discs were identified in the lumbar segment.



Follow Up Questions: Morphologic diagnosis, cause, and name the condition.

*The Diagnostic Exercises are an initiative of the Latin Comparative Pathology Group (LCPG), the Latin American subdivision of The Davis-Thompson Foundation. These exercises are contributed by members and non-members from any country of residence. Consider submitting an exercise! A final document containing this material with answers and a brief discussion will be posted on the CL Davis website (http://www.cldavis.org/diagnostic_exercises.html).

Editor-in-chief: Vinicius Carreira

Associate Editor for this Diagnostic Exercise: Francisco Carvallo